



PATIENT

Kenai Quinones

SPECIES

Canine

BREED

Schnauzer

SEX

Male Neutered

AGE

12 years

WEIGHT

11lbs

INTERPRETED BY

Maggie Machen Lamy,
DVM, DACVIM
(Cardiology)

IMAGING PERFORMED BY

G. Ferrer, DVM

HOSPITAL NAME

Paseos Veterinary
Center

REFERRING VET

Dr. Cruz

INVOICE

31422

DATE

6/19/23

PRESENTING CLINICAL SIGNS

History: Grade 4/6 heart murmur. Heartworm disease. Got HW treatment and started with a cough and syncope episodes.

-Current medications: Pimobendan and Furosemide.

-Abnormal PE/Chem/CBC/UA Results: CBC: WNL CHEM: AMYL: 371 (500-1500) ALP: 12 (23-212).

ECHOCARDIOGRAM FINDINGS

2D, m-mode, color flow and doppler imaging is available. Diffuse thickening of mitral valve leaflets (anterior>posterior) with mild prolapse into the left atrial lumen. Moderate eccentric mitral regurgitation with moderate left atrial dilation. Normal MR velocity. Mildly increased LV diameter with hyperdynamic myocardial function. The tricuspid valve appears subjectively normal, with mild tricuspid regurgitation. Normal velocity. Normal right atrial and ventricular diameter. The pulmonic and aortic valves are normal in morphology and mobility. Normal pulmonic and aortic outflow velocities. No aortic or pulmonic insufficiency. No pericardial or pleural effusion noted. No cardiac tumors observed.

CARDIAC CHART

CANINE CARDIAC PARAMETERS	MR VMAX (m/s)	TR VMAX (m/s)	LA/AO (Boon method)	LA/AO (Heart Base; Swe)	FS (%)	EF (%)	EPSS (cm)
NORMAL PARAMETER	4.5-5.5	<2.7	1.3	<1.6	28-40	40-100	<0.6
PATIENT	4.5	2.6	NM	1.8	61	91	0.18
CANINE CARDIAC PARAMETERS	HR (BPM)	AV VMAX (m/s)	PV MAX (m/s)	BODY WEIGHT (kg)	LA 2D short axis Base view (cm)	LVIDd Avg: 2D and m-mode short axis (cm)	LVIDs Avg: 2D and m-mode short axis (cm)
NORMAL PARAMETER	50-100	0.7-1.7	0.7-1.6	BELOW	BELOW	BELOW	BELOW
PATIENT	130	0.6	1.0	5.0	2.1	3.1	1.2
*Normal chamber parameters expressed as a mean value (SD)				3	1.27 (5.3)	2.46 (2.46)	1.36 (5.5)
BODY WEIGHT DEPENDENT PARAMETERS				5	1.40 (4.5)	2.74 (5.2)	1.60 (4.7)
*Note: All measurements based upon multi-modal images and methods. An average value is reported.				10	1.50 (3.8)	3.27 (3.5)	2.06 (3.1)
				15	1.83 (2.0)	3.71 (2.4)	2.43 (2.1)
				20	2.02 (1.9)	4.14 (2.2)	2.80 (2.0)
				25	2.18 (2.4)	4.48 (2.9)	3.10 (2.5)
				30	2.33 (3.3)	4.83 (3.9)	3.39 (3.4)
				35	2.48 (4.3)	5.17 (5.0)	3.69 (4.5)
				40	2.62 (5.2)	5.48 (6.1)	3.96 (5.4)
				50	2.88 (7.1)	6.07 (8.3)	4.46 (7.4)

INTERPRETATION OF THE FINDINGS & FURTHER RECOMMENDATIONS

Chronic degenerative valve disease causing moderate mitral and mild tricuspid regurgitation. Moderate left atrial enlargement indicates there is relatively low risk for imminent complication, however risk for progression to spontaneous congestive heart failure in the future is elevated. Mild TR is identified; however, pulmonary pressures are normal. No right heart or MPA enlargement are appreciated, secondary to prior heartworm disease. No additional issues are identified.



PATIENT

Kenai Quinones

Given the risk for progression and results of the EPIC trial, Pimobendan is indicated in this patient as below. Assessment of progression in the future will help predict long term outcome, however prognosis is guarded at this stage (B2).

SPECIES

Canine

While mainstem bronchi compression may certainly be contributing to a chronic increase in coughing, other primary airway contributions should also be considered in light of historical HW disease (infectious/inflammatory, early COPD/chronic bronchitis, etc.). Consider hydrocodone for any mechanical component due to cardiomegaly. **Screening chest radiographs are recommended.** No indication for continued diuretic therapy prior to CHF.

BREED

Schnauzer

SEX

Male Neutered

No definitive cardiac cause for syncope is seen in this study (i.e., no PAH, no obvious rupture or tears, reasonable cardiac output, etc.) and other causes should be considered. These possible causes include vasovagal events, intermittent arrhythmias, neurologic/systemic issues, etc. That being said, if the episodes are occurring with significant exertion there certainly is a possibility that regurgitant volume is involved and Pimobendan may help. The history of heartworm treatment must also be considered, as a worm embolus can certainly lead to acute onset of syncope. If the syncope is always cough related the controlling the symptom should improve the episodes.

AGE

12 years

WEIGHT

11lbs

Omega fatty acid supplementation and mild salt restriction may also be of some long-term benefit. Monitor for development of a progressive cough, labored breathing, exercise intolerance or collapse episodes.

INTERPRETED BY

Maggie Machen Lamy,
DVM, DACVIM
(Cardiology)

Once on the medication for 3-5 days, anesthetic risk is considered mildly elevated. Cardiac protective drug choices (opioid/benzodiazepine premedication, Propofol or alfaxalone induction, iso or sevo gas) are recommended. Monitor for arrhythmias, hypotension, and hypoxia both intra and post-operatively and intervene as necessary. Judicious IV fluid rates are recommended to avoid fluid overload. Avoid heart rate stimulating drugs such as atropine unless clinically indicated.

IMAGING PERFORMED BY

G. Ferrer, DVM

PLAN

Baseline BP is recommended with monitoring every 6 months. Institute heart muscle support Pimobendan 0.3mg/kg PO q12h. Consider hydrocodone as discussed. If syncope persists despite adequate cough control, other possibilities should be considered. No indication for continued diuretic therapy.

HOSPITAL NAME

Paseos Veterinary
Center

Recommend monitor for progression with a recheck echocardiogram in 6 months, sooner if any development of clinical signs.

REFERRING VET

Dr. Cruz

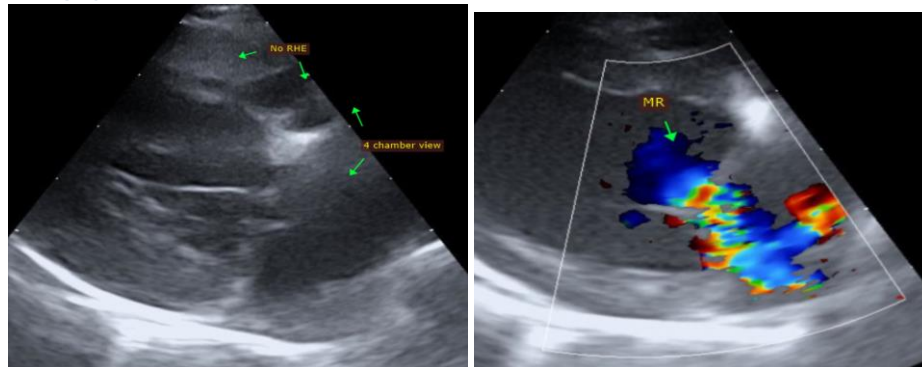
INVOICE

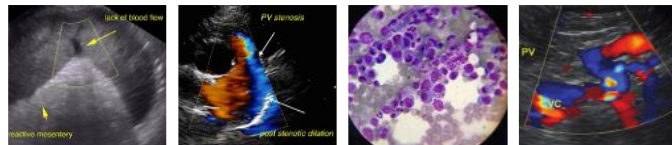
31422

DATE

6/19/23

IMAGES





PATIENT

Kenai Quinones

The information and recommendations provided are based on the images presented by the referring veterinarian. No evaluation can be communicated regarding pathology that was not visible in the image/video clips provided.

SPECIES

Canine

Thank you for this referral. This report was generated using transcription software, and minor dictation errors may be present. If the clinical or image interpretation does not parallel your findings or if I can be of any further assistance, please contact me.

BREED

Schnauzer

Maggie Machen Lamy, DVM
Diplomate of the American College of Veterinary Internal Medicine (Cardiology)
info@sonopath.com

SEX

Male Neutered

AGE

12 years

WEIGHT

11lbs

INTERPRETED BY

Maggie Machen Lamy,
DVM, DACVIM
(Cardiology)

**IMAGING
PERFORMED BY**

G. Ferrer, DVM

HOSPITAL NAME

Paseos Veterinary
Center

REFERRING VET

Dr. Cruz

INVOICE

31422

DATE

6/19/23